

This paper is part of the Special Issue on [Sports Science and Neurorehabilitation: Advances in Biomechanics and Rehabilitation](#).  
**Guest Editor:** Prof. Danilo Donati, Policlinico di Modena, Modena, Italy; Dr. Roberto Tedeschi, Facoltà di Medicina e Chirurgia, Bologna, Italy

Received October 23, 2024, accepted February 21, 2025, publication date for online-first March 20, 2025.

## Letter

# Navigating Thumb Ligament Pathology: From Injury to Recovery

Roberto Tedeschi<sup>1</sup>, Paolo Boccolari<sup>2</sup> and Danilo Donati<sup>2,3,4</sup>

<sup>1</sup> Department of Biomedical and Neuromotor Sciences, Alma Mater Studiorum, University of Bologna, Bologna, Italy.

<sup>2</sup> Clinical and Experimental Medicine PhD Program, University of Modena and Reggio Emilia, 41121 Modena, Italy.

<sup>3</sup> Physical Therapy and Rehabilitation Unit, Policlinico di Modena, 41125 Modena, Italy.

<sup>4</sup> Azienda Ospedaliero, Universitaria di Modena Policlinico.

\* Corresponding Author Email: [roberto.tedeschi2@unibo.it](mailto:roberto.tedeschi2@unibo.it)

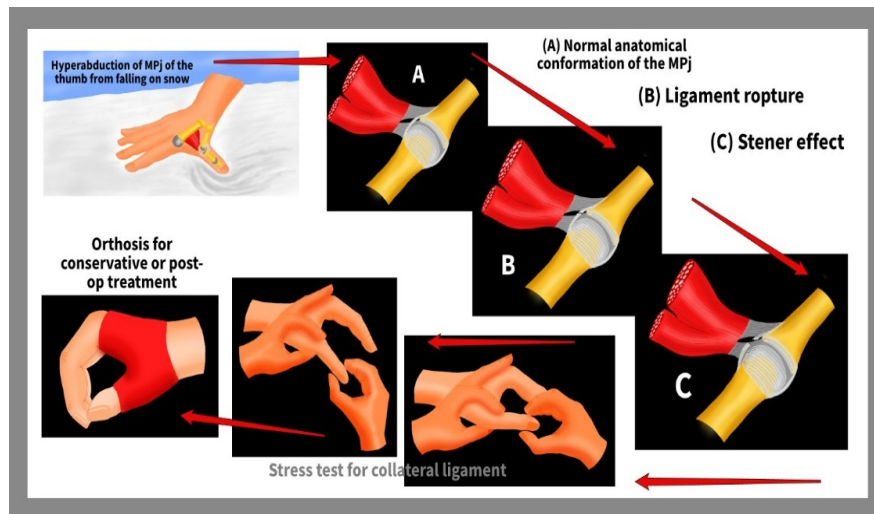
Dear Editor,

The metacarpophalangeal (MP) joint of the thumb functions predominantly as a hinge, facilitating flexion and extension while also allowing limited abduction–adduction and rotational movements. Both active and passive stabilizers contribute to its overall stability, with joint morphology playing a secondary role in this function.<sup>1</sup> The passive stabilizers include the volar plate (VP), which integrates two sesamoid bones, and the main and accessory collateral ligaments. The active stabilizers are classified into intrinsic muscles—abductor pollicis brevis (APB), flexor pollicis brevis (FPB), and adductor (ADD), and extrinsic muscles—long extensor of the thumb (LET), short extensor of the thumb (SET), and long flexor of the thumb (LFT).

The ulnar collateral ligament (UCL) of the thumb comprises two components: the primary and accessory ligaments. The primary ligament runs obliquely, from the dorsal side of the metacarpal head to the volar base of the first phalanx.<sup>2</sup> In contrast, the accessory ligament, which lies more superficially and volarly, merges with the volar plate and inserts at the base of the first phalanx. In extension, the accessory ligament becomes taut, while the primary ligament tightens during flexion, particularly around 30°. As the joint flexes, the accessory ligament slides proximally alongside the volar plate, allowing some degree of joint laxity—approximately 6° in extension and 12° in flexion during the varus–valgus stress test. The management of thumb ligament pathologies can significantly benefit from the integration of advanced clinical engineering technologies. These technologies offer tools to improve diagnostic accuracy, personalize treatment plans, and monitor recovery progress with greater precision. This document explores how advanced imaging, biomechanical modeling, and wearable devices can support the recovery process, enhancing diagnostic accuracy and therapeutic effectiveness.

Injuries to the MP joint frequently occur as a result of hyperabduction or hyperextension, often leading to UCL damage. Such trauma may also involve the dorsal capsule and volar plate, potentially causing volar subluxation of the

joint. Chronic UCL insufficiency, because of its dorsal location relative to the joint's center of rotation, can result in a supination deformity of the first phalanx as it rotates around the intact radial collateral ligament (Figure 1).



**FIGURE 1.** Management and evaluation of ulnar collateral ligament injuries of the thumb.

Hyperabduction of the thumb MP joint can result in UCL injuries, as shown in the series from normal anatomy (Figure 1A), through ligament rupture (Figure 1B), to the development of a Stener lesion (Figure 1C). The figure also illustrates the use of an orthosis for conservative or postoperative care, alongside the proper technique for performing a collateral ligament stress test.

Ulnar collateral ligament injuries commonly involve its distal insertion, occasionally accompanied by an avulsion fracture at the base of the phalanx.<sup>3</sup> Injuries can also occur in the ligament's central or proximal regions. In case of ligament discontinuity, the interposition of the adductor aponeurosis between the torn ligament ends can prevent healing, leading to a Stener lesion.<sup>4</sup>

Clinical evaluation begins with an examination of the trauma history and physical appearance, where swelling and bruising are commonly observed. In severe cases, volar–radial subluxation of the first phalanx may be evident. Tenderness is typically present over the ulnar aspect of the MP joint.

The varus–valgus stress test is essential for determining ligament integrity. This test should always be compared with the contralateral hand and performed in both extension and 30° of flexion. Stabilization of the metacarpal neck is necessary while lateral stress is applied to the phalanx. Any phalanx rotation can obscure a ligament injury. Biomechanical modeling and simulation play a crucial role in understanding ligament stress in the thumb. Using Finite Element Modeling (FEM) techniques, researchers can digitally recreate anatomical structures and evaluate how the UCL responds to varying degrees of stress. These models support the planning of therapeutic, surgical, and conservative interventions by providing an accurate forecast of post-treatment joint stability. Laxity exceeding 30°, or more than 15°, compared to the unaffected side, strongly suggests UCL rupture. Laxity in flexion alone points to the involvement of primary ligament, while laxity in both flexion and extension indicates a more extensive injury to both ligament portions. Laxity only in extension may suggest an isolated volar plate injury.

Advanced imaging technologies, such as high-resolution ultrasound and three-dimensional (3D) magnetic resonance imaging (MRI), allow for a more precise evaluation of ligament structures. These tools can be paired with digital

stress tests, which quantify the biomechanical response of the ligament. Such technologies, supported by 3D models, offer clinical engineers the opportunity to simulate specific thumb movements and predict ligament behavior under various stresses, thereby enhancing diagnostic assessments and reducing the risk of diagnostic errors.<sup>5</sup>

Ulnar collateral ligament injuries are categorized into three grades. Grade 1 involves ligament strain with no detectable laxity; Grade 2 presents with some laxity but a firm end point during the stress test, indicating a partial tear; and Grade 3 is characterized by significant laxity with a soft end point, suggesting complete rupture. Engineered orthoses represent an evolving therapeutic solution. With the development of adaptive designs and advanced materials, these orthoses can accommodate progressive changes in thumb stability, providing targeted support and comfort without restricting essential movements for rehabilitation. Advances in orthotic engineering allow for lighter and more durable devices that can be customized to support each stage of recovery. Looking forward, the integration of artificial intelligence (AI) algorithms with engineering technologies promises to further enhance the management of ligament injuries. Predictive systems powered by AI would identify individuals at the risk of injury and optimize rehabilitation plans by automatically monitoring patient progress. Such integrated approaches represent an exciting prospect for rehabilitation medicine and clinical engineering.

### **AUTHOR CONTRIBUTIONS**

Conceptualization, P.B.; Validation, D.D.; Data Curation, P.B.; Writing–Original Draft Preparation, P.B.; Writing–Review & Editing, D.D. and R.T.

### **FUNDING**

This research received no external funding.

### **DATA AVAILABILITY STATEMENT**

Not applicable.

### **CONFLICTS OF INTEREST**

The authors declare they have no competing interests.

### **ETHICS APPROVAL AND CONSENT TO PARTICIPATE**

Not applicable.

### **CONSENT FOR PUBLICATION**

Not applicable.

### **FURTHER DISCLOSURE**

Not applicable.

## REFERENCES

1. Avery, D.M., Caggiano, N.M., Matullo, K.S. Ulnar collateral ligament injuries of the thumb: A comprehensive review. *Orthop Clin North Am.* 2015;46(2):281–292. <https://doi.org/10.1016/j.ocl.2014.11.007>.
2. Harley, B.J., Werner, F.W., Green, J.K. A biomechanical modeling of injury, repair, and rehabilitation of ulnar collateral ligament injuries of the thumb. *J Hand Surg Am.* 2004;29(5):915–920. <https://doi.org/10.1016/j.jhsa.2004.04.017>.
3. Gluck, J.S., Balutis, E.C., Glickel, S.Z. Thumb ligament injuries. *J Hand Surg Am.* 2015;40(4):835–842. <https://doi.org/10.1016/j.jhsa.2014.11.009>.
4. Ishizuki, M., Sugihara, T., Wakabayashi, Y., et al. Stener-like lesions of collateral ligament ruptures of the metacarpophalangeal joint of the finger. *J Orthop Sci.* 2009;14(2):150–154. <https://doi.org/10.1007/s00776-008-1301-z>.
5. Boccolari, P., Pantaleoni, F., Tedeschi, R., et al. The mechanics of the collateral ligaments in the metacarpophalangeal joints: A scoping review. *Morphologie.* 2024;108(361):100770. <https://doi.org/10.1016/j.morpho.2024.100770>.

**Copyright © 2025.** This is an open-access article distributed under the terms of the Creative Commons Attribution License (CC BY): *Creative Commons - Attribution 4.0 International - CC BY 4.0*. The use, distribution or reproduction in other forums is permitted, provided the original author(s) and the copyright owner(s) are credited and that the original publication in this journal is cited, in accordance with accepted academic practice. No use, distribution or reproduction is permitted which does not comply with these terms.